Journal of Medical Microbiology (2010), **59**, 736–739 DOI 10.1099/jmm.0.016485-0

Case Report

Three cases of *Arcanobacterium pyogenes*-associated soft tissue infection

Kannaiyan Kavitha,[1] R. Latha,[1] C. Udayashankar,[2] K. Jayanthi[1] and P. Oudeacoumar[2]

[1]Department of Microbiology, Aarupadai Veedu Medical College & Hospital, Pondicherry, India

[2]Department of Dermatology, Aarupadai Veedu Medical College & Hospital, Pondicherry, India

Correspondence
R. Latha
latha_kumar71@yahoo.com

Received 7 October 2009
Accepted 9 March 2010

Arcanobacterium pyogenes is an established but often unrecognized human pathogen. *A. pyogenes* may also be misidentified as *Arcanobacterium haemolyticum*, which gives remarkably similar results in conventional biochemical tests. In this study, we have reported three cases of wound infections associated with *A. pyogenes* and also on the bacteriological characteristics which are relevant for identification of these isolates. The negative reverse CAMP test, the ability to produce acid from xylose and to hydrolyse gelatin and the positive β-glucuronidase test clearly differentiated *A. pyogenes* from other closely related species. All three isolates were uniformly susceptible to penicillin, ampicillin, amoxicillin–clavulanic acid, ceftriaxone and gentamicin, variably susceptible to tetracycline and erythromycin and uniformly resistant to cotrimoxazole. Only a few confirmed cases have been reported throughout the world and therefore the diagnostic evaluation of this organism is emphasized.

Introduction

Arcanobacterium pyogenes is a Gram-positive, pleomorphic bacillus (Palmer & Whipple, 1999). It is a common inhabitant of the upper respiratory, urogenital and gastrointestinal tracts (Jost *et al.*, 2001) of many domestic animal species and is primarily an animal pathogen causing pyogenic infections in cattle (Wüst *et al.*, 1993). *A. pyogenes* has not been isolated as part of the normal human flora (Jost & Billington, 2005). It is a rare cause of infection in humans (Plamondon *et al.*, 2007; Meyer & Reboli, 2005; Winn *et al.*, 2006; Wüst *et al.*, 1993), mostly related to living in rural areas and contact with animals (Plamondon *et al.*, 2007; Levy *et al.*, 2009). Clinical laboratories in developing countries do not routinely attempt to identify this organism and to date there are no case reports from India. We report here three cases of wound infections associated with *A. pyogenes*, the first report from India to the best of our knowledge.

Case reports

Case 1

A 49-year-old man was admitted to our hospital in June 2009 with an infected diabetic foot ulcer of 1 month duration. His medical history was unremarkable except for insulin-dependent diabetes of 7 years duration. He was seronegative for HIV antibodies. He was a farmer who was living in a rural area where cattle grazing was common. On general examination he was afebrile. His cardiovascular and respiratory examinations were unremarkable. The ulcer was 2×2 cm, about 2 cm above the left lateral malleolus, with a discharge of serosanguinous pus. The laboratory investigations revealed a leukocyte count of 19.5×10^6 cells l^{-1} with 95 % polymorphonuclear neutrophils and an erythrocyte sedimentation rate of 90 mm h^{-1}.

Direct Gram stain of the pus showed plenty of polymorphonuclear leukocytes, with pleomorphic Gram-positive bacilli and Gram-positive cocci arranged singly, in pairs and in short chains of not more than four. Cultures on blood agar yielded heavy growth of *A. pyogenes* and *Enterococcus faecalis*, both identified by standard biochemical methods. Both organisms were sensitive to amoxicillin with clavulanic acid and erythromycin. In addition, *A. pyogenes* was also sensitive to penicillin, ampicillin and ceftriaxone while *E. faecalis* was resistant to penicillin and ampicillin. *E. faecalis* was also sensitive to vancomycin. Both were resistant to cotrimoxazole and tetracycline. The foot lesion slowly recovered with debridement of necrotic tissue, and treatment with ceftriaxone 2 g per day intramuscularly given in two divided doses, ofloxacin 600 mg per day orally in three divided doses and metronidazole 1.5 g per day orally in three divided doses. This treatment was initiated before the culture and sensitivity report was available, and as there was no discharge, the same treatment was continued for 1 week and later switched over to amoxicillin with clavulanic acid orally 500 mg two times daily for another week. The wound had healed satisfactorily at follow up 1 month later.

Downloaded from www.sgmjournals.org by
IP: 93.91.26.97
On: Wed, 29 Jul 2015 15:53:36
016485 © 2010 SGM Printed in Great Britain

Fig. 1. Post Hansen's trophic ulcer over the right lateral malleolus.

Case 2

A 65-year-old man came to the dermatology department in July 2009 complaining of a non-healing ulcer on the right ankle for the previous 1 year. His past history was significant in being treated for Hansen's disease 10 years previously. He also came from a rural area with close contact with animals. His body temperature was 39 °C and the cardiovascular and respiratory examinations were unremarkable. Local examination of the trophic ulcer revealed a 2 × 3 cm oozing ulcer (Fig. 1). Pus from the site was sent to the microbiology department. Direct Gram stain of the pus disclosed numerous polymorphonuclear leukocytes and pleomorphic Gram-positive and Gram-negative bacilli. Pus on culture yielded heavy growth of *A. pyogenes* and *Proteus vulgaris*, identified by standard biochemical methods. Antibiotic susceptibility testing by the disc diffusion (Kirby–Bauer) method revealed that *A. pyogenes* was susceptible to penicillin, ampicillin, gentamicin, tetracycline, ceftriaxone and erythromycin and resistant to cotrimoxazole whereas *P. vulgaris* was sensitive only to amikacin and resistant to ampicillin, amoxicillin–clavulanic acid, gentamicin, tetracycline, ceftriaxone and cotrimoxazole. The patient was started intravenously with ceftazidime sulbactam 1 g b.d. and amikacin 1 g o.d. for 1 week and switched over to cefexime 500 mg b.d. orally for 1 week. There was no discharge from the wound 20 days later and he was discharged on request and lost to follow up.

Case 3

A 35-year-man came to the dermatology department with an infected scabies lesion of 2 months duration. On local examination, excoriated papules with crusted erosions were seen over the finger web spaces. Direct Gram stain of the pus demonstrated plenty of polymorphonuclear leukocytes along with numerous Gram-positive bacilli and Gram-positive cocci in clusters. Cultures yielded *A. pyogenes* and *Staphylococcus aureus* as identified by standard biochemical methods. The antibiotic sensitivity pattern of *A. pyogenes* was similar to that of the isolate in case 1 except for its resistance to erythromycin. *S. aureus* was sensitive to amoxicillin with clavulanic acid, erythromycin, oxacillin and vancomycin and resistant to ampicillin and cotrimoxazole. The patient was started on single applications of 5 % permethrin every 6 h and oral ivermectin 12 mg single dose to treat the scabies; amoxicillin with clavulanic acid 2 g per day orally in two divided doses was given for 1 week to treat the secondary infections. The patient recovered completely.

Characteristics of the three different cases of *A. pyogenes* wound infections described here are summarized in Table 1.

Microbiological investigations

The three isolates on 5 % blood agar grew small, grey–white, convex colonies with a clear zone of β-haemolysis after 24 h of aerobic incubation, and upon further incubation for 48 h, the colonies increased in size and had a much wider zone of haemolysis (Fig. 2a, b). Gram stain on cultures showed Gram-positive branching bacilli

Table 1. Overview of the present cases and their clinical presentation

	Age of patient (year)/sex	Site of infection	Duration of infection	Underlying disease/ risk factors	Contact with cattle	Organisms recovered	Treatment	Outcome
Case 1	49/M	2 cm above left lateral malleolus	One month	Diabetic for 7 years	+	*A. pyogenes*, *E. faecalis*	Ceftriaxone, ofloxacin and metronidazole	Cured
Case 2	65/M	Right ankle	One year	Treated for Hansen's 10 years previously	+	*A. pyogenes*, *P. vulgaris*	Ceftazidime sulbactam and amikacin	Not determined
Case 3	35/M	Finger web spaces	Two months	Scabies with secondary infection	+	*A. pyogenes*, *S. aureus*	Permethrin, ivermectin and amoxicillin–clavulanate	Cured

Downloaded from www.sgmjournals.org by
IP: 93.91.26.97
On: Wed, 29 Jul 2015 15:53:36

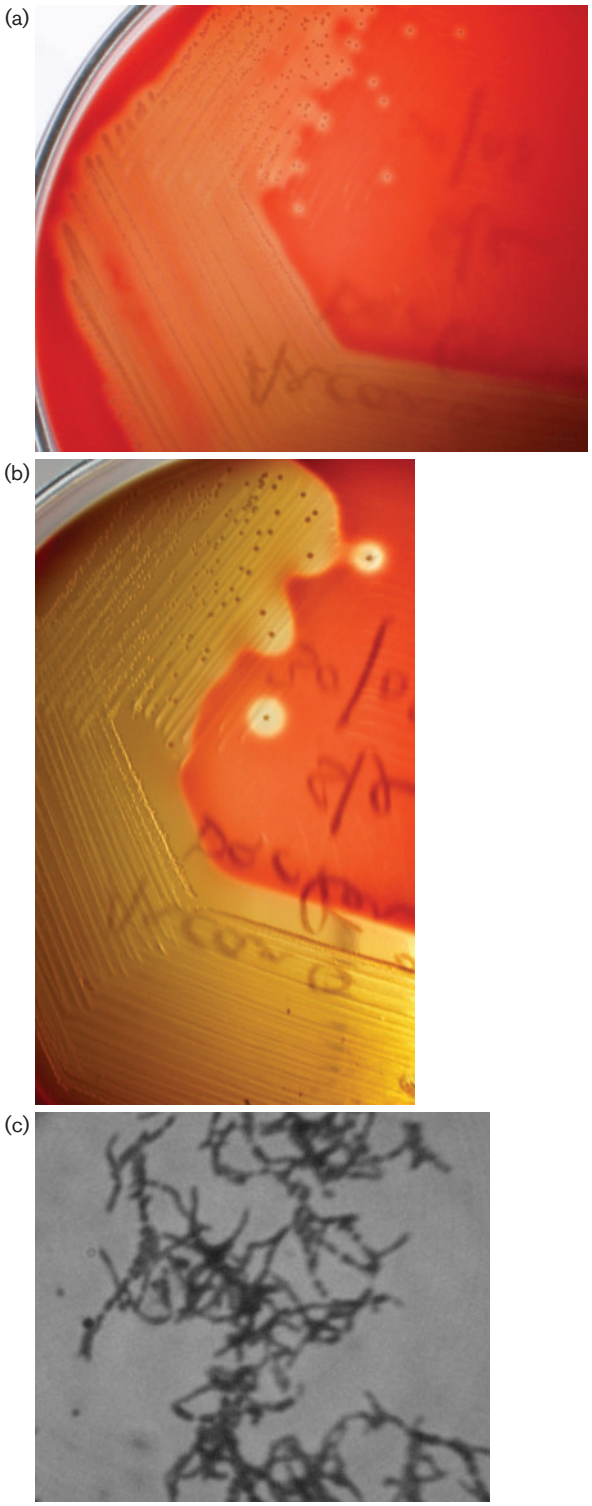

Fig. 2. (a) Blood agar plate examined after 24 h showing β-haemolytic, small, grey–white, convex colonies. (b) The same blood agar plate examined after 48 h showing a wider zone of β-haemolysis. (c) Gram stain from culture showing Gram-positive branching bacilli.

(Fig. 2c). All the Gram-positive branching bacilli isolates were catalase-negative and negative for the reverse CAMP test and were able to hydrolyse gelatin. Also all three *A. pyogenes* isolates fermented glucose and xylose with the production of acid but were variable for sucrose and mannitol and also for the reduction of nitrates to nitrites. In addition, all the three strains were positive for the β-glucuronidase and *o*-nitrophenyl-β-D-galactopyranoside tests. The isolates were unable to hydrolyse aesculin and did not produce urease (Table 2). Based on these phenotypic characters, the organism was identified as *A. pyogenes*. Disc diffusion susceptibility testing by the Kirby–Bauer method showed that all three isolates were uniformly susceptible to penicillin, ampicillin, ceftriaxone and gentamicin, but variably susceptible to tetracycline and erythromycin and uniformly resistant to cotrimoxazole.

Discussion

A. pyogenes, recently reclassified from the genus *Actinomyces* (Ramos *et al.*, 1997), is the predominant animal pathogen within the *Arcanobacterium* genus. Although human infections caused by this organism have been reported since 1940, the validity of these reports is questionable because of a lack of microbiological data ensuring a definite distinction of this agent from closely related bacteria such as *Arcanobacterium haemolyticum* (Winn *et al.*, 2006). All three isolates in the present study were *A. pyogenes*, the species most infrequently isolated from humans. This species was easily differentiated from *A. haemolyticum* and *Arcanobacterium bernardiae* as it was obviously β-haemolytic at 24 h, reverse CAMP test-negative, hydrolysed gelatin, fermented xylose and was positive in the β-glucuronidase test (Winn *et al.*, 2006). We identified our isolates based on their phenotypic characters. We would like to emphasize these phenotypic tests for the

Table 2. Biochemical characteristics of *Arcanobacterium pyogenes* isolated from the three case patients

Test	*A. pyogenes* isolates		
	Case 1	Case 2	Case 3
β-Haemolysis	+	+	+
Aesculin hydrolysis	−	−	−
Gelatin hydrolysis	+	+	+
Nitrate reduction	−	−	+
Urease	−	−	−
o-Nitrophenyl-β-D-galactopyranoside	+	+	+
Acid from:			
Glucose	+	+	+
Mannitol	+	−	−
Sucrose	−	+	−
Xylose	+	+	+
β-Glucuronidase	+	+	+

Downloaded from www.sgmjournals.org by
IP: 93.91.26.97
On: Wed, 29 Jul 2015 15:53:36

identification of *A. pyogenes*, particularly in developing countries where molecular identification is not feasible in all routine laboratories.

A. pyogenes can act as a primary pathogen, but is more commonly isolated in mixed infections (Jost & Billington, 2004). In our study also, all three strains were isolated from mixed infections. It has also been reported that infection with *A. pyogenes* is often a sequel to early tissue injury or to infection with other bacteria (Palmer & Whipple, 1999). It is probable that this was the likely cause in our cases also. Two patients had predisposing factors of diabetes and a past history of Hansen's disease. Also, all three patients were residing in a rural area in close contact with animals, further substantiating the relatedness of the infection to living in rural areas and contact with animals.

A. pyogenes is usually susceptible to benzyl penicillin, ampicillin, gentamicin and macrolides and resistant to cotrimoxazole, streptomycin and tetracyclines (Jost *et al.*, 2001). Similarly, the isolates from all three patients were susceptible to penicillin, ampicillin and gentamicin but variably susceptible to tetracycline and erythromycin and uniformly resistant to cotrimoxazole. However, susceptibility standards were not available because *A. pyogenes* rarely causes disease in humans.

Recent studies in the literature have shown only a few confirmed cases of human infections with *A. pyogenes* throughout the world (Meyer & Reboli, 2005; Winn *et al.*, 2006) and none reported from India. Furthermore, many early reports are plagued by limited details on the microbiological tests performed, raising the possibility of misidentification (Plamondon *et al.*, 2007). In addition, *A. pyogenes* may also be misidentified as *A. haemolyticum*, which gives similar results in conventional biochemical tests. We can also hypothesize that the organism is probably under-reported due to its innocuous, coryneform appearance.

In conclusion, our report serves to further highlight the fact that *A. pyogenes* can be pathogenic to human beings and that microbiologists should consider this organism while processing clinical material.

References

Jost, B. H. & Billington, S. J. (2004). *Corynebacterium* and *Arcanobacterium*. In *Pathogenesis of Bacterial Infection in Animals*, 3rd edn, pp. 77–86. Edited by C. L. Gyles, J. F. Prescott, J. G. Songer & C. O. Thoen. Ames, IA: Blackwell Publishing.

Jost, B. H. & Billington, S. J. (2005). *Arcanobacterium pyogenes*: molecular pathogenesis of an animal opportunist. *Antonie Van Leeuwenhoek* **88**, 87–102.

Jost, B. H., Songer, J. G. & Billington, S. J. (2001). Cloning, expression, and characterization of a neuraminidase gene from *Arcanobacterium pyogenes*. *Infect Immun* **69**, 4430–4437.

Levy, C. E., Pedro, R. J., Von Nowakonski, A., Holanda, L. M., Brocchi, M. & Ramo, M. C. (2009). *Arcanobacterium pyogenes* sepsis in farmer, Brazil. *Emerg Infect Dis* **15**, 1131–1132.

Meyer, D. K. & Reboli, A. C. (2005). Other Corynebacteria and *Rhodococcus*. In *Principles and Practice of Infectious Diseases*, 6th edn, pp. 2465–2478. Edited by G. L. Mandell, R. Dolin & J. E. Bennet. New York: Churchill-Livingstone.

Palmer, M. V. & Whipple, D. L. (1999). *Arcanobacterium pyogenes* as a cause of fatal pleuropneumonia after capture and transport of white-tailed deer (*Odocoileus virginianus*). *J Vet Diagn Invest* **11**, 468–471.

Plamondon, M., Martinez, G., Raynal, L., Touchette, M. & Valiquette, L. (2007). A fatal case of *Arcanobacterium pyogenes* endocarditis in a man with no identified animal contact: case report and review of the literature. *Eur J Clin Microbiol Infect Dis* **26**, 663–666.

Ramos, C. P., Foster, G. & Collins, M. D. (1997). Phylogenetic analysis of the genus *Actinomyces* based on 16S rRNA gene sequences: description of *Arcanobacterium phocae* sp. nov., *Arcanobacterium bernardiae* comb. nov., and *Arcanobacterium pyogenes* comb. nov. *Int J Syst Bacteriol* **47**, 46–53.

Winn, W., Jr, Allen, S., Janda, W., Koneman, E., Procop, G., Schreckenberger, P. & Woods, G. (2006). Other Coryneform bacteria. In *Koneman's Color Atlas and Textbook of Diagnostic Microbiology*, 6th edn, pp. 817–823. Philadelphia: Lippincott Williams & Wilkins.

Wüst, J., Martinetti, G. D., Lüthy-Hottenstein, J., Brun, F. & Altwegg, M. (1993). Isolation of Gram-positive rods that resemble but are clearly distinct from *Actinomyces pyogenes* from mixed wound infection. *J Clin Microbiol* **31**, 1127–1135.

Downloaded from www.sgmjournals.org by
IP: 93.91.26.97
On: Wed, 29 Jul 2015 15:53:36