Journal of Medical Microbiology (2010), **59**, 120–123 DOI 10.1099/jmm.0.012930-0

Case Report

Zoonotic transmission of *Streptococcus equi* subsp. *zooepidemicus* from a dog to a handler

Y. Abbott,[1] E. Acke,[1] S. Khan,[2] E. G. Muldoon,[3] B. K. Markey,[1] M. Pinilla,[1] F. C. Leonard,[1] K. Steward[4] and A. Waller[4]

[1]Veterinary Sciences, Veterinary Sciences Centre, School of Agriculture, Food Science and Veterinary Medicine, University College Dublin, Belfield, Dublin 4, Ireland

[2]Beacon Hospital, Sandyford, Dublin 18, Ireland

[3]St James's Hospital, James's Street, Dublin 8, Ireland

[4]Centre for Preventive Medicine, Animal Health Trust, Newmarket, UK

Correspondence
Y. Abbott
yvonne.abbott@ucd.ie

Received 18 May 2009
Accepted 7 September 2009

This is, to the best of our knowledge, the first case report to describe the apparent transmission of *Streptococcus equi* subsp. *zooepidemicus* from an infected dog to a handler who subsequently developed severe systemic infection. Characterization of the haemolytic streptococci isolated from both the patient and the dog, by phenotypic and molecular analysis, confirmed the canine and human isolates were identical.

Introduction

Streptococcus equi subsp. *zooepidemicus* (*S. zooepidemicus*) belongs to the Lancefield group C along with *Streptococcus equi* subsp. *equi*, *Streptococcus dysgalactiae* and *Streptococcus dysgalactiae* subsp. *equisimilis* (*S. equisimilis*). It is a commensal organism found on the tonsils, upper respiratory tract, skin and urogenital tract of horses (Anzai *et al.*, 2000; CFSPH, 2005), but is not considered part of the normal tonsillar flora in either dogs (Devriese *et al.*, 1992) or man (Fox *et al.*, 1993). An opportunistic pathogen, it is associated with respiratory infections and suppurative disease in many animal species, including horses, cows, pigs, sheep, monkeys, guinea pigs, mink and gerbils (Barnham *et al.*, 1987; Chanter, 1997). In dogs, *S. zooepidemicus* has been associated with septicaemia, wound infections (Timoney, 2004) and with cases of acute fatal haemorrhagic streptococcal pneumonia (HSP) at dog kennels (BVA, 2008; Pesavento *et al.*, 2008), and more recently in a household pet (Gibson & Richardson, 2008). An increased severity of disease was associated with the presence of *S. zooepidemicus* in a study of canine infectious respiratory disease (Chalker *et al.*, 2003).

In humans, infections caused by *S. zooepidemicus* are a rare event, resulting in meningitis, bacteraemia, acute nephritis, septic arthritis, pneumonia, and in some cases, death of the patient (Barnham *et al.*, 1987; Efstratiou, 1997; Thorley *et al.*, 2007; Ural *et al.*, 2003). In the majority of these cases, consumption of unpasteurized milk or direct contact with horses was considered the most likely source of infection.

Abbreviations: BVA, British Veterinary Association; HSP, haemorrhagic streptococcal pneumonia; MLST, multilocus sequence typing; ST, sequence type.

Case report

A 1-year-old male Jack Russell terrier presented with a 9 month history of lower respiratory tract problems, pyrexia and bilateral mucopurulent nasal discharge. The dog lived on a farm, which provided short-term accommodation for horses. The dog had free access to all areas of the farm, including the horses and their environment. Clinical examination revealed bilateral mucopurulent nasal discharge, a marked tachypnoea (respiratory rate 80 breaths per min) and harsh lung sounds over both lung fields. The dog was pyrexic, with a rectal temperature of 39.7 °C. Radiographs revealed bilateral symmetrical consolidation of the lung fields. Nasal swabs were taken for routine culture and a transtracheal lavage was performed, with samples submitted for cytology and bacterial culture. In order to help stabilize the respiratory signs, treatment involving placement of a nasal catheter to provide oxygen therapy was provided. During this procedure, the dog sneezed over the handler, spreading mucous secretions into the handler's eyes, nose and facial area. Saline was used to clean the handler's face and rinse out the eyes. Blood samples from the dog revealed a white blood cell count of 26.4×10^9 cells l^{-1} (normal range 6–17×10^9 cells l^{-1}), mature neutrophils at 19.54×10^9 cells l^{-1} (normal range 3–11.5×10^9 cells l^{-1}) and monocytes at 2.38×10^9 cells l^{-1} (normal range 0.2–1.3×10^9 cells l^{-1}). Intravenous fluid therapy was administered along with antibiotic therapy (20 mg intravenous amoxicillin/clavulanic acid kg^{-1} every 8 h and 5 mg intravenous enrofloxacin kg^{-1}). Cytology on transtracheal lavage samples was consistent with marked suppurative pneumonia. The nasal swabs and transtracheal lavage samples yielded pure growth of a β-haemolytic streptococcus that was identified as *S. zooepidemicus*.

Downloaded from www.sgmjournals.org by
IP: 93.91.26.97
On: Mon, 31 Aug 2015 21:42:24
012930 © 2010 SGM Printed in Great Britain

Intravenous antibiotic treatment, fluid therapy and coupage/nebulization were continued until day 5 when the dog was discharged with a 2 month course of oral amoxicillin/clavulanic acid at 18.4 mg kg^{-1} to be administered twice daily.

Six weeks after the initial presentation, the dog was reassessed. There were no abnormalities on clinical examination, thoracic radiographs revealed no abnormalities, and complete blood count and serum biochemistry were unremarkable. Nasal and oropharyngeal swab cultures were negative and there has been no recurrence of the clinical signs to date.

On day 2, the dog handler began to feel unwell, experiencing symptoms of stiffness in the neck and chest area, fever, headache and general malaise. On day 3 the patient attended a general practitioner and was prescribed penicillin for 5 days. Nasal and oropharyngeal swabs were taken and submitted for culture. However, the patient's condition did not improve, and on day 8 the patient was referred to hospital for further investigation. On admission, the patient's pulse rate was 67 beats per min and temperature was 36.2 °C. Blood pressure was 85/45 mmHg initially, which later recovered. O_2 saturations were 97 % on room air. First and second heart sounds were audible, with no added sounds and no murmur. The patient's chest was clinically clear, with no crepitations and no rhonchi. Palpation of the abdomen presented no tenderness and no organomegaly. Conjunctivitis was evident, with neck stiffness and headache. Blood results on admission were as follows: 13.1 g haemoglobin dl^{-1} (normal range 13–17 g dl^{-1}), white cell count 6.6×10^9 cells l^{-1} (normal range 4–10×10^9 cells l^{-1}), platelets 226×10^9 cells l^{-1} (normal range 150–350×10^9 cells l^{-1}), 86 μmol creatinine l^{-1} (normal range 44–80 μmol l^{-1}), 1.67 ng C reactive protein l^{-1} (normal value <5 ng l^{-1}), 44 U γ-glutamyl transpeptidase l^{-1} (normal range 12–64 U l^{-1}), 129 U lactate dehydrogenase l^{-1} (normal range 125–243 U l^{-1}) and the erythrocyte sedimentation rate was 10 mm h^{-1} (normal range 0–20 mm h^{-1}). A computed tomography brain scan was performed and found to be normal, with no evidence of raised intracranial pressure. A lumbar puncture was performed and a cerebral spinal fluid sample was obtained. Analysis demonstrated that no white cells were present, and no bacteria were evident in the direct Gram-stain or following culture. Blood and urine cultures were also clear. The nasal and throat samples taken on day 3 yielded heavy growths of β-haemolytic streptococci that were identified as *S. zooepidemicus*. The patient was treated with cefalexin, administered intravenously for the first 5 days, followed by oral administration for a further 7 days. Tests for other infectious causes, such as Epstein–Barr virus, cytomegalovirus and human immunodeficiency virus, were all negative. It was considered that the symptoms were likely to be associated with the *S. zooepidemicus* isolated from the patient's throat and nose. The penicillin treatment may have accounted for the negative blood culture result. The patient was discharged after 5 days, and throat and nasal swabs taken a month later were negative.

A prospective study was carried out on the farm several weeks after the initial case to ascertain the possible source of this particular strain of *S. zooepidemicus*. Oropharyngeal swabs from horses present on the farm, nasal and oropharyngeal samples taken from the owners, as well as environmental samples, all cultured negative. However, an oropharyngeal swab collected from a companion dog in the household was found to be positive for *S. zooepidemicus*. The second dog, an 8 year old cross breed, had no evidence of any abnormalities on clinical examination, and was perceived as being healthy by the owners. This investigation was approved by the University College Dublin Human Research Ethics Committee.

Microbiological methods

All specimens were cultured directly onto blood agar (BA) [Columbia blood agar base (Oxoid) supplemented with 5 % defibrinated sheep blood] and then enriched in Todd–Hewitt broth (Oxoid). Plates and broths were incubated for 18 h at 37 °C. Broths were then subcultured onto BA containing Staph/Strep selective supplement (Oxoid; SR70E), which contains colistin and nalidixic acid, and were incubated overnight at 37 °C. Colonies were identified as group C *Streptococcus* species by colony morphology, haemolysis, Gram-stain and catalase and agglutination reaction with streptococcal grouping reagents (Streptococcal Grouping kit; Oxoid). The group C streptococci were identified to the species level using the API Rapid ID 32 Strep kit (bioMérieux). Antimicrobial susceptibility testing carried out according to the recommendations of the Clinical and Laboratory Standards Institute (CLSI, 2005) revealed all isolates to be sensitive to the following antimicrobial agents: cefalotin, amoxicillin/clavulanic acid, tetracycline, trimethoprim/sulfadiazine, enrofloxacin, marbofloxacin and penicillin G.

Comparison of the two canine and the human *S. zooepidemicus* isolates, by PFGE (Leonard & Carroll, 1997) was carried out, with 40 U *Sma*I and a restriction time of 24 h. Previously isolated but unrelated clinical equine strains, equine A, B and C, were also included for comparison. The banding patterns revealed that the isolates from the handler were indistinguishable, whilst the pattern from the infected dog's isolate had a one band difference to these strains. The isolate from the asymptomatic dog differed significantly from the infected dog and human strains. These isolates were also dissimilar to the clinical equine strains used for comparison (Fig. 1).

The isolates were further characterized using multilocus sequence typing (MLST), as previously described (Webb *et al.*, 2008). The strains from the infected dog and human were both sequence type (ST) 178, whilst the clinical equine strains A, B and C, were ST-180, ST-5 and ST-39, respectively, and the companion dog isolate was ST-173.

Downloaded from www.sgmjournals.org by
IP: 93.91.26.97
On: Mon, 31 Aug 2015 21:42:24

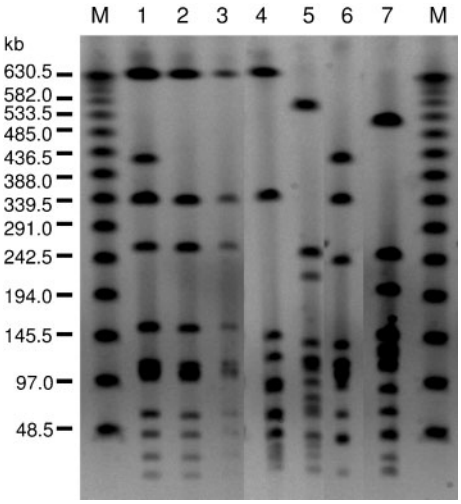

Fig. 1. PFGE analysis of *S. zooepidemicus* isolates following macrorestriction of genomic DNA with *Sma*I. M, DNA size marker (kb); 1, sample from infected dog; 2, human nasal sample; 3, sample from human throat; 4, equine A sample; 5, equine B sample; 6, equine C sample; 7, sample from companion dog.

Discussion

This is believed to be the first report to describe the apparent transmission of *S. zooepidemicus* from an infected dog to a human, demonstrating the communicability of this zoonotic species and the possibility of acquiring infection from dogs.

S. zooepidemicus has been reported as an opportunistic pathogen associated with invasive infections in laboratory and domestic animals (Francis *et al.*, 1993). A commensal organism in horses, it is also associated with respiratory tract infections in foals and young horses (Chanter, 1997; Downar *et al.*, 2001) and with equine abortion (Giles *et al.*, 1993). In cattle, *S. zooepidemicus* has been described as an occasional cause of mastitis (Edwards *et al.*, 1988), and in dogs is associated with respiratory conditions such as canine infectious respiratory disease and HSP (Chalker *et al.*, 2003; Pesavento *et al.*, 2008). It is not, however, normally associated with chronic respiratory infection in dogs. Infection is uncommon in man (Francis *et al.*, 1993) and *S. zooepidemicus* accounts for less than 1 % of all bacteraemias (CFSPH, 2005), but has been described as the most virulent of the Lancefield Group C streptococci that infect humans (Bradley *et al.*, 1991). Mortality rates following infections with *S. zooepidemicus* are twice as high as those associated with cases of *S. equisimilis* (Bradley *et al.*, 1991).

Reports describing human infections by *S. zooepidemicus* appear as sporadic individual reports (Boucher *et al.*, 2002; Thorley *et al.*, 2007) or as occasional reports of large epidemic outbreaks affecting numerous individuals following ingestion of contaminated cheese (Sesso *et al.*, 2005). Clinical presentations are variable, and may include mild upper respiratory tract signs, pneumonia, septic arthritis, septicaemia and meningitis (Barnham *et al.*, 1987; Ghoneim & Cooke, 1980; Downar *et al.*, 2001). In the majority of cases, the likely routes of transmission have included close contact with an infected horse or the drinking of unpasteurized milk (Efstratiou, 1997; Francis *et al.*, 1993; Low *et al.*, 1980).

The dog involved in this case appears to have developed chronic respiratory tract infection following acquisition of this zoonotic pathogen, probably as a result of contact with horses. Comparison of the isolates from the dog and the handler by PFGE indicated that they were very similar, differing by a single band, which might be related to the acquisition or loss of a plasmid or bacteriophage, which could be clarified on genome sequencing. Similar reports, investigating transmission of *S. zooepidemicus* from other animals to humans, have also used PFGE when comparing strains (Downar *et al.*, 2001; Jovanovic *et al.*, 2008; Kuusi *et al.*, 2006). However, it is difficult to compare PFGE results between these studies. The *S. zooepidemicus* MLST scheme permits the identification of different alleles directly from the nucleotide sequences of ~400–500 bp internal fragments of seven housekeeping genes (Webb *et al.*, 2008). The scheme is fully portable and data can be readily compared with those of previous studies through the use of an electronic database (http://pubmlst.org/szooepidemicus/). MLST confirmed that the canine and human isolates shared an identical ST, ST-178. A strain sharing this ST was previously isolated from a case of equine abortion in the UK during 2003, but this ST appears unrelated to other strains previously isolated from dogs (http://pubmlst.org/szooepidemicus/), and to the isolates recovered from the horses and the healthy companion dog in this study.

It therefore appears that transmission of this strain from the affected dog to the handler occurred, and resulted in clinical illness. Whilst none of the horses present on the farm at the time of screening were found to be carriers of *S. zooepidemicus*, based on clinical history, it is conceivable that the dog may have been infected many months previously from a horse that subsequently left the farm or resolved its infection. The asymptomatic carriage of a different strain of *S. zooepidemicus* (ST-173) in a healthy companion dog, resident on the same farm, suggests that transmission from horses to dogs may commonly occur. Interestingly, strains of ST-173 have also been isolated from a severe outbreak of HSP in dogs in the USA during 2006 (Pesavento *et al.*, 2008), and a single locus variant of ST-173, ST-18, was recovered from four greyhounds affected in a UK outbreak of HSP during 2008 (Webb *et al.*, 2008), suggesting that *S. zooepidemicus* strains of these related types may be particularly adept at infecting dogs. The future analysis of the genome sequences of these isolates may reveal the genetic basis behind this apparent increased ability to infect dogs. The equine isolates identified in this study shared STs with other equine isolates previously listed in the MLST database (http://pubmlst.org/szooepidemicus/). In light of this report, the authors would advise animal handlers and veterinary clinicians to wear appropriate protective equip-

Downloaded from www.sgmjournals.org by
IP: 93.91.26.97
On: Mon, 31 Aug 2015 21:42:24

ment (safety glasses and face masks) when dealing with animals presenting with respiratory symptoms.

Acknowledgements

The authors wish to thank Dr Brendan Healy, Professor Seamus Fanning and Bernadette Leggett (University College Dublin) for their technical assistance.

References

Anzai, T., Walker, J. A., Blair, M. B., Chambers, T. M. & Timoney, J. F. (2000). Comparison of the phenotypes of *Streptococcus zooepidemicus* isolated from tonsils of healthy horses and specimens obtained from foals and donkeys with pneumonia. *Am J Vet Res* **61**, 162–166.

Barnham, M., Cole, G., Efstratiou, A., Tagg, J. R. & Skjold, S. A. (1987). Characterization of *Streptococcus zooepidemicus* (Lancefield group C) from human and selected animal infections. *Epidemiol Infect* **98**, 171–182.

Boucher, C., Higgins, R., Nadeau, M. & Vincent, C. (2002). A case of zoonosis associated with *Streptococcus equi* ssp. *zooepidemicus*. *Can Vet J* **43**, 123–124.

Bradley, S. F., Gordon, J. J., Baumgartner, D. D., Marasco, W. A. & Kauffman, C. A. (1991). Group C streptococcal bacteremia: analysis of 88 cases. *Rev Infect Dis* **13**, 270–280.

BVA (2008). NGRC reports on greyhound deaths. *Vet Rec* **162**, 463.

CFSPH (2005). *Streptococcosis*, disease data sheet. Ames, IA: Center for Food Security and Public Health. http://www.cfsph.iastate.edu/Factsheets/pdfs/streptococcosis.pdf

Chalker, V. J., Brooks, H. W. & Brownlie, J. (2003). The association of *Streptococcus equi* subsp. *zooepidemicus* with canine infectious respiratory disease. *Vet Microbiol* **95**, 149–156.

Chanter, N. (1997). Streptococci and enterococci as animal pathogens. *Soc Appl Bacteriol Symp Ser* **26**, 100S–109S.

CLSI (2005). *Performance Standards for Antimicrobial Disk Diffusion Susceptibility Tests*, approved standard, 9th edn, 15th informational supplement M100–S15. Wayne, PA: Clinical and Laboratory Standards Institute.

Devriese, L. A., Cruz Colque, J. I., De Herdt, P. & Haesebrouck, F. (1992). Identification and composition of the tonsillar and anal enterococcal flora of dogs and cats. *J Appl Bacteriol* **73**, 421–425.

Downar, J., Willey, B. M., Sutherland, J. W., Mathew, K. & Low, D. E. (2001). Streptococcal meningitis resulting from contact with an infected horse. *J Clin Microbiol* **39**, 2358–2359.

Edwards, A. T., Roulson, M. & Ironside, M. J. (1988). A milk-borne outbreak of serious infection due to *Streptococcus zooepidemicus* (Lancefield Group C). *Epidemiol Infect* **101**, 43–51.

Efstratiou, A. (1997). Pyogenic streptococci of Lancefield groups C and G as pathogens in man. *Soc Appl Bacteriol Symp Ser* **26**, 72S–79S.

Fox, K., Turner, J. & Fox, A. (1993). Role of β-hemolytic group C streptococci in pharyngitis: incidence and biochemical characteristics of *Streptococcus equisimilis* and *Streptococcus anginosus* in patients and healthy controls. *J Clin Microbiol* **31**, 804–807.

Francis, A. J., Nimmo, G. R., Efstratiou, A., Galanis, V. & Nuttall, N. (1993). Investigation of milk-borne *Streptococcus zooepidemicus* infection associated with glomerulonephritis in Australia. *J Infect* **27**, 317–323.

Ghoneim, A. T. & Cooke, E. M. (1980). Serious infection caused by group C streptococci. *J Clin Pathol* **33**, 188–190.

Gibson, D. & Richardson, G. (2008). Haemorrhagic streptococcal pneumonia in a dog. *Vet Rec* **162**, 423–424.

Giles, R. C., Donahue, J. M. & Hong, C. B. (1993). Cause of abortion, stillbirth and perinatal death in horses: 3,527 cases (1986–1991). *J Am Vet Med Assoc* **203**, 1170–1175.

Jovanovic, M., Stevanovic, G., Tosic, T., Stosovic, B. & Zervos, M. J. (2008). *Streptococcus equi* subsp. *zooepidemicus* meningitis. *J Med Microbiol* **57**, 373–375.

Kuusi, M., Lahti, E., Virolainen, A., Hatakka, M., Vuento, R., Rantala, L., Vuopio Varkila, J., Seuna, E., Karppelin, M. & other authors (2006). An outbreak of *Streptococcus equi subspecies zooepidemicus* associated with consumption of fresh goat cheese. *BMC Infect Dis* **6**, 36.

Leonard, R. B. & Carroll, K. C. (1997). Rapid lysis of gram-positive cocci for pulsed-field gel electrophoresis using achromopeptidase. *Diagn Mol Pathol* **6**, 288–291.

Low, D. E., Young, M. R. & Harding, G. K. M. (1980). Group C streptococcal meningitis in an adult: probable acquisition from a horse. *Arch Intern Med* **140**, 977–978.

Pesavento, P. A., Hurley, K. F., Bannasch, M. J., Artiushin, S. & Timoney, J. F. (2008). A clonal outbreak of acute fatal hemorrhagic pneumonia in intensively housed (shelter) dogs caused by *Streptococcus equi* subsp. *zooepidemicus*. *Vet Pathol* **45**, 51–53.

Sesso, R. & Pinto, S. W. L. (2005). Epidemic glomerulonephritis due to *Streptococcus zooepidemicus* in Nova Serrana, Brazil. *Kidney Int* **68**, S132–S136.

Thorley, A. M., Cambell, D., Moghal, N. E. & Hudson, S. (2007). Post streptococcal acute glomerulonephritis secondary to sporadic *Streptococcus equi* infection. *Pediatr Nephrol* **22**, 597–599.

Timoney, J. F. (2004). Streptococcus. In *Pathogenesis of Bacterial Infections in Animals*, 3rd edn, pp. 23–42. Edited by C. L. Gyles, J. F. Prescott, J. G. Songer & C. O. Thoen. Oxford: Blackwell Publishing.

Ural, O., Tuncer, I., Dikici, N. & Aridogan, B. (2003). *Streptococcus zooepidemicus* meningitis and bacteraemia. *Scand J Infect Dis* **35**, 206–207.

Webb, K., Jolley, K. A., Mitchell, Z., Robinson, C., Newton, J. R., Maiden, M. C. & Waller, A. (2008). Development of an unambiguous and discriminatory multilocus sequence typing scheme for the *Streptococcus zooepidemicus* group. *Microbiology* **154**, 3016–3024.

Downloaded from www.sgmjournals.org by
IP: 93.91.26.97
On: Mon, 31 Aug 2015 21:42:24